

Nathaniel W. Yang, MD

Department of Otorhinolaryngology
College of Medicine – Philippine General Hospital
University of the Philippines Manila

Blunting of the Scutum: A Key Feature in the Radiologic Diagnosis of Acquired *Cholesteatoma*

The determination of the presence of acquired *cholesteatoma* in the middle ear and mastoid is one of the most common indications for computerized tomographic (CT) imaging of the temporal bone. While the presence of a soft tissue density in the *mesotympanum*, *epitympanum* or *antrum* is a feature of *cholesteatomatous* disease, CT imaging cannot reliably differentiate soft tissue densities caused by *cholesteatoma*, middle ear effusion or fluid completely filling the middle ear and mastoid air cell system, granulation tissue, brain, or other soft tissue densities that may fill the air-containing space.^{1,2} Bone erosion is the radiologic *sine qua non* of a *cholesteatoma*. In the absence of bone erosion, a *cholesteatoma* may be present but cannot be diagnosed on CT imaging studies. One of the earliest abnormalities of a *cholesteatoma* that can be appreciated on a CT scan is erosion of the scutum, which is the medial aspect of the roof of the external auditory canal, and where the tympanic membrane attaches superiorly. Scutum erosion is most easily seen on coronal CT images.²

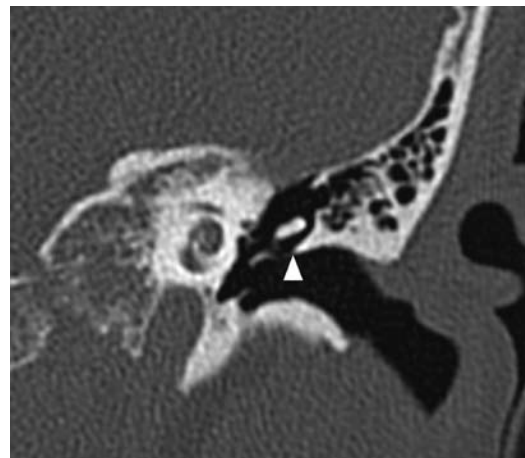


Figure 1. This is a coronal CT image of a temporal bone with no known middle ear pathology. It passes through the temporal bone at the level of the *cochlea*, and uses a bone window algorithm with a window width of 4,000 H. The scutum can be identified as the sharp-edged superomedial border of the external auditory canal (white arrowhead).

Correspondence: Nathaniel W. Yang, MD
Department of Otorhinolaryngology
Ward 10, Philippine General Hospital
Taft Ave., Ermita, Manila 1000
Phone: (632) 526 4360
Fax: (632) 525 5444
Email: nwyang@gmx.net
Reprints will not be available from the author.

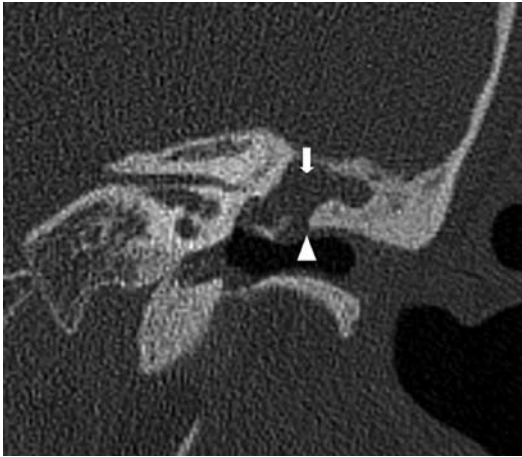


Figure 2. This is a coronal CT image passing through the level of the internal auditory canal in a patient with known middle ear disease. The *epitympanum* is occupied by a soft tissue density (white arrow). The scutum (white arrowhead) is blunted, very much like the tip of a used, unsharpened pencil. Clinical examination and surgical findings confirm the presence of an acquired *cholesteatoma* in the *epitympanum* and *mastoid antrum*.

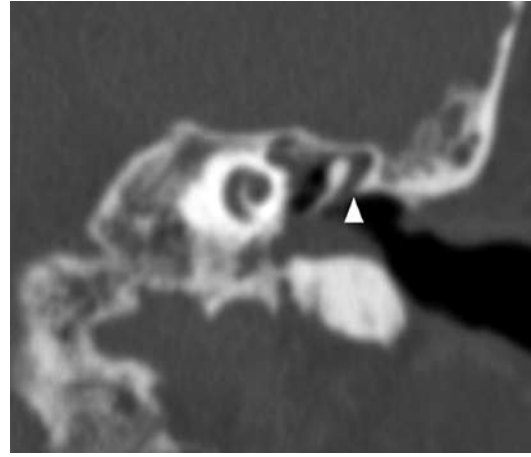


Figure 3. This is a coronal CT image passing through the level of the *cochlea* in a patient with chronic middle ear effusion. The tympanic membrane was intact, with no evidence of attic retraction pockets. The CT scan was taken four days after myringotomy with aspiration of the middle ear fluid. Persistent clear fluid draining from the ear raised the suspicion of a CSF leak. This scan was radiologically interpreted as a case of *cholesteatoma*, although the scutum is not blunted (white arrowhead), and clinical examination did not show any evidence of such pathology. This case illustrates the need for clinicians to be vigilant in corroborating a radiologic diagnosis of *cholesteatoma*.

REFERENCES:

- 1 Johnson DW, Voorhees RL, Lufkin RB et al. Cholesteatomas of the temporal bone: Role of computed tomography. *Radiology* 1983; 148: 733-737.
- 2 Weissman JL. Hearing loss. *Radiology* 1996; 199: 593-611.